

Oligosarcoma Arising from Oligodendroglioma-A case report

Alison Ho^{1*}, Shivum Desai², Thanh N. Nguyen³, Jonathon Cooke⁴

¹Department of Neurosurgery, Desert Regional Medical Center, Palm Springs, California, USA

²Arizona College of Osteopathic Medicine, Glendale, Arizona, USA

³University of Washington School of Medicine, Seattle, Washington, USA

⁴Naval Medical Center San Diego, California, USA

***Corresponding Author:** Alison Ho, Department of Neurosurgery, Desert Regional Medical Center, Palm Springs, California, USA

Received date: 16 June 2022; **Accepted date:** 07 July 2022; **Published date:** 14 July 2022

Citation: Ho A, Desai S, Nguyen TN, Cooke J (2022) Oligosarcoma Arising from Oligodendroglioma-A case report. J Med Case Rep Case Series 3(08): <https://doi.org/10.38207/JMCRCS/2022/AUG03080562>

Copyright: © 2022 Alison Ho. This is an open-access article distributed under the terms of the Creative Commons Attribution License, which permits unrestricted use, distribution, and reproduction in any medium, provided the original author and source are credited.

Abstract

High-grade Oligodendroglioma with a sarcomatous component, Oligosarcoma, is a rare malignant tumor with features of oligodendroglial lineage and histological features corresponding to the World Health Organization (WHO) grade III, with sarcoma components [1,2]. Only a few cases of oligosarcoma with oligodendroglial components have been reported. Here we present the case of a patient treated for an oligodendroglioma who did not have initial optimal systemic therapy and continued to have a recurrence of the disease, which then progressed to oligosarcoma.

Keywords: Oligosarcoma, MRI, Oligodendroglioma, sarcomatous, tumor

Introduction

Oligodendroglioma, a neoplasm widely regarded as morphologically and clinically stable in nature, typically presents with a better prognosis than those astrocytic tumors [11-13]. This comprises approximately 0.5-1.2 % of all primary brain tumors and carries a unique histological feature of uniformly round nuclei with surrounding cytoplasmic clearing, the classic "fried egg" appearance [11,17]. One of the hallmark genetic findings of Oligodendroglioma is the combined whole arm deletion of chromosomes 1q and 19p. This chromosomal abnormality is associated with a favorable response to chemotherapy and improved patient outcomes, with a median overall survival of more than 14 years for patients treated with radiation and chemotherapy [11,17,20]. Here, we describe the case of a patient diagnosed and treated for Oligodendroglioma, who subsequently experienced a recurrence of the disease, which was found to be

Oligodendroglioma with a sarcomatous component, so call oligosarcoma.

Rubinstein first discovered Oligodendroglioma with sarcomatous features in 1972 [21]. According to World Health Organization (WHO) classification, oligosarcoma is a malignant tumor of oligodendroglial lineage containing sarcomatous histological features and is categorized as WHO grade III [1,2]. In 2007 Rodriguez et al. published the most extensive case series regarding oligosarcoma. His study followed seven patients initially diagnosed with Oligodendroglioma but developed recurrent tumors with sarcomatous components [4]. Since then, only a few reports have been published in the literature, highlighting the rarity of oligosarcoma [3,14,15,16,19].

Case

A 46-year-old female patient presented with difficulty speaking. Magnetic resonance imaging (MRI) of the patient's brain revealed a mass lesion in the left frontal lobe. The patient underwent gross total tumor resection via the left frontal approach. The histopathological diagnosis of the resected lesion was oligodendroglioma World Health Organization (WHO) Grade II. She was started on adjuvant radiation therapy during her postoperative course. As a result of her treatments, the patient did well and was periodically followed until nine years later, when a recurrent mass was identified on a routine MRI, demonstrating a mixed cystic, solid mass in the left frontal lobe region. The patient underwent revision surgery and resection of the

recurrent mass. The histopathological diagnosis was oligodendroglioma World Health Organization (WHO) Grade III with a sarcomatous component (**Figure 1**). Fluorescence in situ hybridization (FISH) analysis revealed a 1p/19q codeletion. The patient subsequently started temozolomide chemotherapy.

Three years after her second surgery, a follow-up MRI brain with gadolinium contrast again revealed a growing mass at the site of the resection bed. Therefore, the patient underwent a third surgery using the same approach as her primary operations. Residual scar tissue was found near the postero-lateral aspect of the patient's primary motor strip; therefore, the patient only had a subtotal resection of the

recurrent mass. Radiotherapy was planned to follow the patient's third operation, in addition to temozolomide chemotherapy, which was resumed once the final pathological diagnosis again showed recurrent

high-grade Oligodendroglioma with the sarcomatous component (Figure 2).

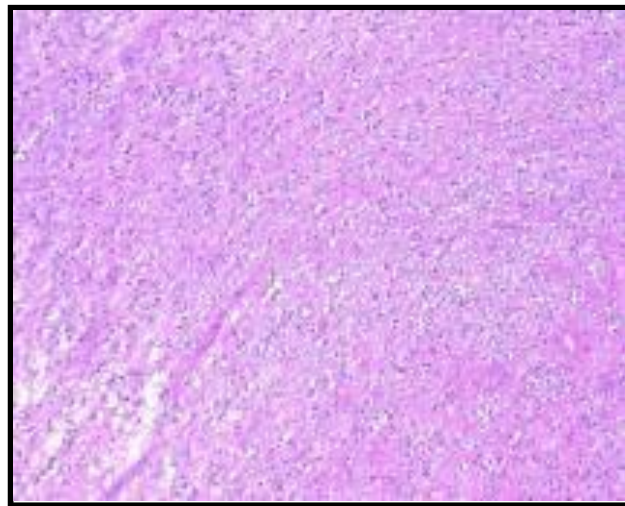


Figure 1: H&E- round nuclei with surrounding cytoplasmic clearing (perinuclear halo") brisk mitotic activity, hyper cellularity, endothelial hypertrophy, and necrosis

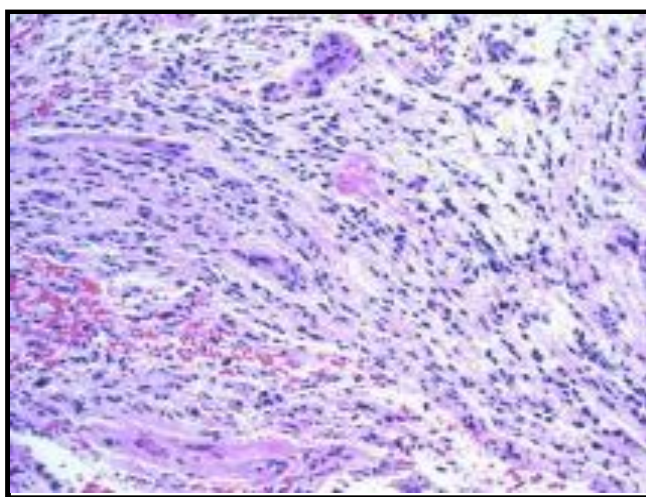


Figure 2: H&E- high grade features: increased mitotic activity, microvascular proliferation, necrosis with sarcomatous components

Discussion

Oligosarcoma commonly presents in the 3rd to 5th decades of life as a recurrent to the surgical site of previous oligodendroglioma resection with or without treatment after months to years [3,4,14,15,16,19]. The disease typically affects the frontal and temporal lobes of the brain, and patients will present with symptoms such as vertigo, seizures, headache, nausea, and vomiting [4,14,15,16,19]. Oligosarcomas retain many of the histological characteristics of oligodendrogliomas (monotonous round nuclei, perinuclear halos, and fine chromatin [4,5,12,14,23]) with the additional features specific to the novel sarcomatous components such as eosinophilia cytoplasm, spindle cells, mitotic figures, and cellular necrosis [4,14,15,16,19]. However, upon recurrence, oligosarcomas show a histology more consistent with anaplastic lesions, including hypercellularity, endothelial hypertrophy, brisk mitotic activity, irregular hyperchromatic nuclei, necrosis, and, occasionally, mucus-filled cysts [4,5,12,14,23]. Immunobiological staining of oligosarcomas shows Glial fibrillary acidic protein (GFAP) and S-100 protein reactivity secondary to the presence of typical glial cells and positive staining for alpha-smooth muscle actin and desmin as a result of sarcomatous features [4,14,15,16,19].

As outlined in a case series by Rodriguez et al. in 2007, the glial components of oligosarcomas expressed both GFAP and S-100 in all

cases. In contrast, the sarcomatous component at least focally showed smooth muscle actin, CD34, S-100 protein, and epithelial membrane antigen reactivity. FISH studies demonstrated 1p/19q codeletion in 5 cases, no evidence of deletion in 1 point, and technically failed in 1 case. Three of the five instances showed 1p/19q codeletion in the sarcomatous component. Genetic analysis of this disease implicates a single nucleotide polymorphism on chromosome 8q24.21 in the evolution from Oligodendroglioma to oligosarcoma [4,8,6,14,19]. As stated in the literature, the most common method of treatment typically involves combination chemotherapy with procarbazine [Matulane], lomustine [CeeNU], and vincristine (PCV); and radiation following surgical resection [4]. However, recent reports note that immunotherapy with temozolomide following surgical resection is sufficient and adequate [14,15,16,19]. But they remain interested in the early use of PCV for these tumors due to evidence of a better prognosis [5]. The genetic marker of 1p/19q codeletion is the most significant and favorable allelic loss due it is associated with sensitivity to both chemotherapies and better outcomes with radiotherapy [4,5]. Most importantly, gross total resection is the standard gold treatment for oligosarcoma [7].

Furthermore, there was previously controversy due to the suspicion that postoperative radiation therapy for oligodendroglioma treatment could trigger the subsequent sarcomatous transformation into

oligosarcoma. However, this theory has been quashed due to multiple reports of oligosarcomas following oligodendrogliomas in patients with no history of radiation therapy [4,14,16,19]. Per Rodriguez et al.,

Conclusion

Maximal safe gross total resection is a gold standard in neuro-oncology to establish early diagnosis and reduce the mass effect, often the cause of symptoms and neurological deficits. Of note, intraoperative sensory evoked potential and phase reversal are essential information. They serve as guidance for the resection plane and can also show possible brain plasticity on subsequent surgery within the perilesional area. If this reorganization took place, this could allow for the total removal of the tumor without a cost to the patient's neurological deficits and decrease the tumor's burden, which allows for reduced radio therapeutic portal size, increased effectiveness of chemotherapy, and limited sampling error, which often occurs in cases in which a biopsy sample alone is obtained [1]. Moreover, one should recognize that rare anaplastic and sarcomatous features can occur in recurrent previously resected low-grade

oligodendroglioma without preceding systemic treatment, for which early testing for a molecular marker of 1p/19q codeletion is one of the significant climacterics beside gross total resection in oligodendroglioma treatment to improve patient's prognosis and prevent progression of the disease. It is crucial to initiate surgical and optimal medical systemic treatment early to improve overall survival.

Disclosures: The authors have no conflicts of interest and received no funding for this research. This research has never been previously presented and is not currently submitted or pending publication elsewhere.

References

1. E. Herbert (2002) Current diagnosis and treatment of oligodendroglioma. *Neurosurgery Focus* 12(2): E2.
2. Youman, Brain Tumors: An overview of current Histopathologic Classifications, vol. Chapter 96, vol 2–1079.
3. T. Shoji, R. Saito, M. Kanamori, Y. Sonoda, M. Watanabe, and T. Tominaga (2016) Sarcoma-like tumor originating from oligodendroglioma. *Brain Tumor Pathol.* 33(4): 255-260.
4. Rodriguez FJ, Scheithauer BW, Jenkins R, Burger PC, Rudzinskiy P, et al. (2007) Gliosarcoma arising in oligodendroglial tumors ('oligosarcoma'): a clinicopathologic study. *Am. J. Surg. Pathol.* 31(3): 351–362.
5. Bromberg JEC, Bent MJVD (2009) Oligodendrogliomas: Molecular Biology and Treatment. *The Oncologist.* 14(2): 155-163.
6. Jung-Woo Choi (2013) Gliosarcoma with Components of Anaplastic Oligodendroglioma and Unclassifiable Spindle Cells- A Case Report-. *Clin Neuropathol.* 32(3): 165-70.
7. Anderson MD, Gilbert MR (2013) Treatment Recommendations for Anaplastic Oligodendrogliomas That Are Codeleted. *Oncology (Williston Park).* 27(4): 315-20, 322
8. Jenkins RB, Xiao Y, Sicotte H, Decker PA, Kollmeyer TM, et al. (2012) A low-frequency variant at 8q24.21 is strongly associated with risk of oligodendroglial tumors and astrocytomas with IDH1 or IDH2 mutation. *Nature Genetics.* 44(10): 1122-25.
9. Ohgaki H, Kleihues P (2005) Population-based studies on incidence, survival rates, and genetic alterations in astrocytic and oligodendroglial gliomas. *J Neuropath Exp Neurol.* 64(6): 479-89.
10. Dolecek TA, Propp JM, Stroup NE, Kruchko C (2012) CBTRUS statistical report: primary brain and central nervous system tumors diagnosed in the United States in 2005–2009. *Neuro Oncol.* 14(suppl 5): v1-v49.
11. van den Bent MJ, Kros JM, Heimans JJ, Pronk LC, van Groeningen CJ, et al. (1998) Response rate and prognostic factors of recurrent oligodendroglioma treated with procarbazine, CCNU, and vincristine chemotherapy. Dutch Neuro-oncology Group. *Neurology.* 51(4): 1140-5.
12. Engelhard HH, Stelea A, Mundt A (2003) Oligodendroglioma and anaplastic Oligodendroglioma: clinical features, treatment, and prognosis. *Surg Neurol.* 60(5): 443-56.
13. van den Bent MJ, Chinot O, Boogerd W, Bravo Marques J, Taphoorn MJ, et al. (2003) Second-line chemotherapy with temozolomide in recurrent Oligodendroglioma after PCV (procarbazine, lomustine, and vincristine) chemotherapy: EORTC Brain Tumor Group phase II study 26972. *Ann Oncol.* 14(4): 599-602.
14. Yasuda T, Nitta M, Komori T, Kobayashi T, Masui K, et al. (2018) Gliosarcoma arising from oligodendroglioma, IDH mutant and 1p/19q codeleted. *Neuropathology.* 38(1): 41-46.
15. Hiniker A, Hagenkord JM, Powers MP, Aghi MK, Prados MD, et al. (2013) Gliosarcoma arising from an oligodendroglioma (oligosarcoma). *Clin Neuropathol.* 32(3): 165-70.
16. Tanaka S, Hitotsumatsu T, Sugita Y, Ishido K, Ito O, et al. (2018) Gliosarcoma arising from Oligodendroglioma (Oligosarcoma): A case report with genetic analyses. *Pathol Int.* 68(10): 567-573.
17. Wesseling P, van den Bent M, Perry A. (2015) Oligodendroglioma: pathology, molecular mechanisms, and

- markers. *Acta Neuropathol.* 129(6): 809-827.
18. Mohile NA, Messersmith H, Gatson NT, Hottinger AF, Lassman A, et al. (2022) Therapy for Diffuse Astrocytic and Oligodendroglial Tumors in Adults: ASCO-SNO Guideline. *J Clin Oncol.* 40(4): 403-426.
19. Vajtai I, Vassella E, Hewer E, Kappeler A, Reinert MM (2012) Sarcomatous evolution of Oligodendroglioma ("oligosarcoma"): confirmatory report of an uncommon pattern of malignant progression in oligodendroglial tumors. *Pathol Res Pract.* 208(12): 750-5.
20. Bou Zerdan M, Assi HI (2021) Oligodendroglioma: A Review of Management and Pathways. *Front Mol Neurosci.* 14: 722396.
21. Rubinstein LJ (1972) Tumors of the central nervous system. Armed Forces Institute of Pathology. Washington, DC.
22. Suwala AK, Felix M, Friedel D, Stichel D, Schrimpf D, et al. (2022) Oligosarcomas, IDH-mutant are distinct and aggressive. *Acta Neuropathol.* 143(2): 263–281.
23. Fadda A, Vajtai I, Lang J, Henke D, Oevermann, A (2014) Cerebral high-grade Oligodendroglioma with sarcomatous transdifferentiation ("oligosarcoma") in a boxer dog. *Journal of veterinary internal medicine.* 28(6): 1881–1885.